Movement Disorders
Vol. 17, No. 5, 2002, pp. 853–866
© 2002 Movement Disorder Society

Research Review

Stiff Man Syndrome and Related Conditions

Hans-Michael Meinck, MD,[1] and Philip D. Thompson, MD[2]*

[1]*Department of Neurology, Im Neuenheimerfeld, Heidelberg, Germany*
[2]*University Department of Medicine and Department of Neurology, University of Adelaide and Royal Adelaide Hospital, Adelaide, South Australia*

Abstract: The stiff man syndrome (SMS) and its variants, focal SMS, stiff limb (or leg) syndrome (SLS), jerking SMS, and progressive encephalomyelitis with rigidity and myoclonus (PERM), appear to occur more frequently than hitherto thought. A characteristic ensemble of symptoms and signs allows a tentative clinical diagnosis. Supportive ancillary findings include (1) the demonstration of continuous muscle activity in trunk and proximal limb muscles despite attempted relaxation, (2) enhanced exteroceptive reflexes, and (3) antibodies to glutamic acid decarboxylase (GAD) in both serum and spinal fluid. Antibodies to GAD are not diagnostic or specific for SMS and the role of these autoantibodies in the pathogenesis of SMS/SLS/PERM is the subject of debate and difficult to reconcile on the basis of our present knowledge. Nevertheless, evidence is emerging to suggest that SMS/SLS/PERM are manifestations of an immune-mediated chronic encephalomyelitis and immunomodulation is an effective therapeutic approach. © 2002 Movement Disorder Society

Key words: stiff man syndrome; encephalomyelitis; rigidity; spasms

This review of the stiff man syndrome (SMS) and related conditions is based on the experience of the authors and is set in the context of a prospective series collected by one of the authors (H.M.M.) as well as cases reported in the literature. Because of the perceived rarity of the conditions and the uncertainty about diagnosis expressed by many neurologists, the basic clinical features, important diagnostic criteria, and differential diagnosis are considered in detail.

DEFINITION

The term "stiff man syndrome" was introduced by Moersch and Woltman[1] to describe an unusual and previously unrecognised disorder characterised by "progressive fluctuating muscular rigidity and spasm" without other neurological signs. Many cases have been reported since, reaffirming the core clinical features of the syndrome but providing few clues to the cause. A significant development was the discovery of autoantibodies to glutamic acid decarboxylase (antiGADAb),[2] prompting the suggestion that SMS is an autoimmune disease. Greater awareness of the condition in recent years has also led to the recognition of different patterns of presentation of stiff man variants such as focal SMS, "jerking" SMS, and paraneoplastic SMS. Several reports have drawn attention to similarities in the clinical findings in SMS and progressive encephalomyelitis with rigidity and myoclonus (PERM).[3,4] The relationship between the SMS, PERM, and "stiff man variants," the role and significance of antiGADAb and immunomodulatory therapies remain the subject of debate and will be considered further in this review.

EPIDEMIOLOGY

The SMS is generally regarded as a rare condition. However, over a period of 10 years, 20 patients were collected by one of the authors (H.M.M.) from the area surrounding Heidelberg, Germany, with a population of 2 to 3 million. Together with patients referred from outside this region, a total of 68 patients were seen with unexplained stiffness and spasm (Table 1), 20 of whom had classic SMS and 13 had SMS in combination

*Correspondence to: Philip D. Thompson, University Department of Medicine and Department of Neurology, University of Adelaide and Royal Adelaide Hospital, Adelaide, South Australia 5000.
E-mail: philip.thompson@adelaide.edu.au
Published online 23 July 2002 in Wiley InterScience (www.interscience.wiley.com). DOI 10.1002/mds.10279

with another neurological illness (such as neuropathy or stroke). In 6 patients, focal stiffness of a leg (SLS) was seen, and 29 were diagnosed as having PERM. The average age of onset of SMS is in the fifth decade in this series, in accord with other case series and descriptions in the literature.

CLINICAL FEATURES OF SMS

Spasms and Rigidity

Rigidity and muscle stiffness are usually symmetric and most prominent in axial and proximal limb muscles. Lumbar paraspinal rigidity gives rise to a characteristic exaggerated lumbar lordosis, limiting the range of truncal mobility, particularly truncal flexion (Fig. 1A,B). Muscle rigidity fluctuates in severity from a mild increase in tone to board-like stiffness. Severe rigidity renders affected limbs immobile and voluntary movement, particularly walking, becomes slow and awkward. Spasms of increased muscle stiffness are superimposed on the rigidity and occur spontaneously or in response to a variety of external and internal stimuli. Sudden noise, touch, movement, and even anger or fear elicit an increase in muscle stiffness and spasm. Spasms involve the limbs and trunk and typically begin with an abrupt myoclonic jerk followed by tonic activity that slowly subsides over several seconds. Intense pain may accompany the spasm. Movement of a limb or the trunk movement during the myoclonic jerk and subsequent tonic muscle activity may be limited because of simultaneous activation of antagonist muscle pairs, and therefore escape clinical observation. Cutaneous stimulation (light touch or pinprick) of the legs may elicit a crossed flexor withdrawal response, with ipsilateral flexion of the hip and knee, dorsiflexion of the foot, extension and slight abduction of the contralateral leg, and extension of the lumbar trunk. Other movements during a spasm comprise extension and pronation of the arms, extension of the trunk (less frequently truncal flexion), extension and slight abduction of the legs, and inversion of the feet (Fig. 1C). Spasms are usually bilateral, even after unilateral stimulation. Although both stiffness and spasms usually predominate in axial muscles in a symmetric manner, asymmetrical involvement of the feet or even hands was present in 30% of cases and, therefore, is not as rare as suggested in the literature (see Fig. 1D and Table 1). In a recent survey, asymmetry was also noted in 15 of 20 patients.[5] Stiffness and spasms fluctuate throughout the day and lessen or even disappear during sleep or narcosis. Spasms may be severe enough to cause femoral fractures or bend Smith Peterson pins,[6–9] joint subluxation,[10] or herniation of abdominal contents. Myo-

TABLE 1. *Survey of symptoms and signs in 68 patients presenting with muscle stiffness from the Heidelberg registry*

	SLS	SMS	PERM
Patient characteristics			
N	6	33	29
AntiGADAb			
Positive	5 = 83%	23 = 70%	22 = 76%
Negative	1 = 17%	8 = 24%	7 = 24%
Unknown	0	2	0
Anti-amphiphysin Ab			
Positive	0	2 = 6%	0
Female	4	25	17
Male	2	8	12
Age at onset (yr)	30 – 71 (M = 54.6)	17 – 72 (M = 45.5)	13 – 64 (M = 46.0)
Common clinical features			
Core features			
Spasms			
Spontaneous	6	32	26
Reflex	6	31	28
Stiffness			
Permanent	6	23	20
Fluctuating	6	33	28
Distribution			
Generalized	0	7	6
Neck-shoulder-arms	0	9	10
Back-hips-legs	6	30	28
Involvement of			
hands	0	2	5
feet	3	10	18
face	0	2	3
Gross asymmetry	6	4	11
Accessory features			
Gait disturbance	6	29	29
Falls	4	19	20
Injuries	3	11	8
Skeletal deformity	2	19	18
Paroxysmal fear	3	20	15
Excessive startle	3	19	18
Brisk tendon reflexes	3	18	20
Autonomic signs	2	18	20
ICU treatment > 4 days	0	4	7
Sudden death	0	3	3
Misdiagnosis hysteria	5	23	17
Discriminating clinical features			
Ocular motor disturbance	0	0	14
Dysarthria/dysphagia	0	0	10
Neuropsychological disturbance	0	0	8
Babinski sign	0	0	8
Paresis	0	0	6
Vertigo	0	0	6
Ataxia	0	0	5
Nystagmus	0	0	5
Bladder disturbance	0	0	4
Epilepsy	0	0	3
Retinopathy	0	0	1
Chorea	0	0	1

Six patients presented with the stiff limb syndrome (SLS), 33 with the stiff man syndrome (SMS), and progressive encepharomyelitis with rigidity and myoclonus (PERM) was diagnosed in 29 patients. There were no major clinical differences between those presenting with antibodies to glutamic acid decarboxylase (anti-GADAb). Features that discriminate between SMS/SLS and PERM are listed below. Autoantibody status was not known in 2 patients with SMS.

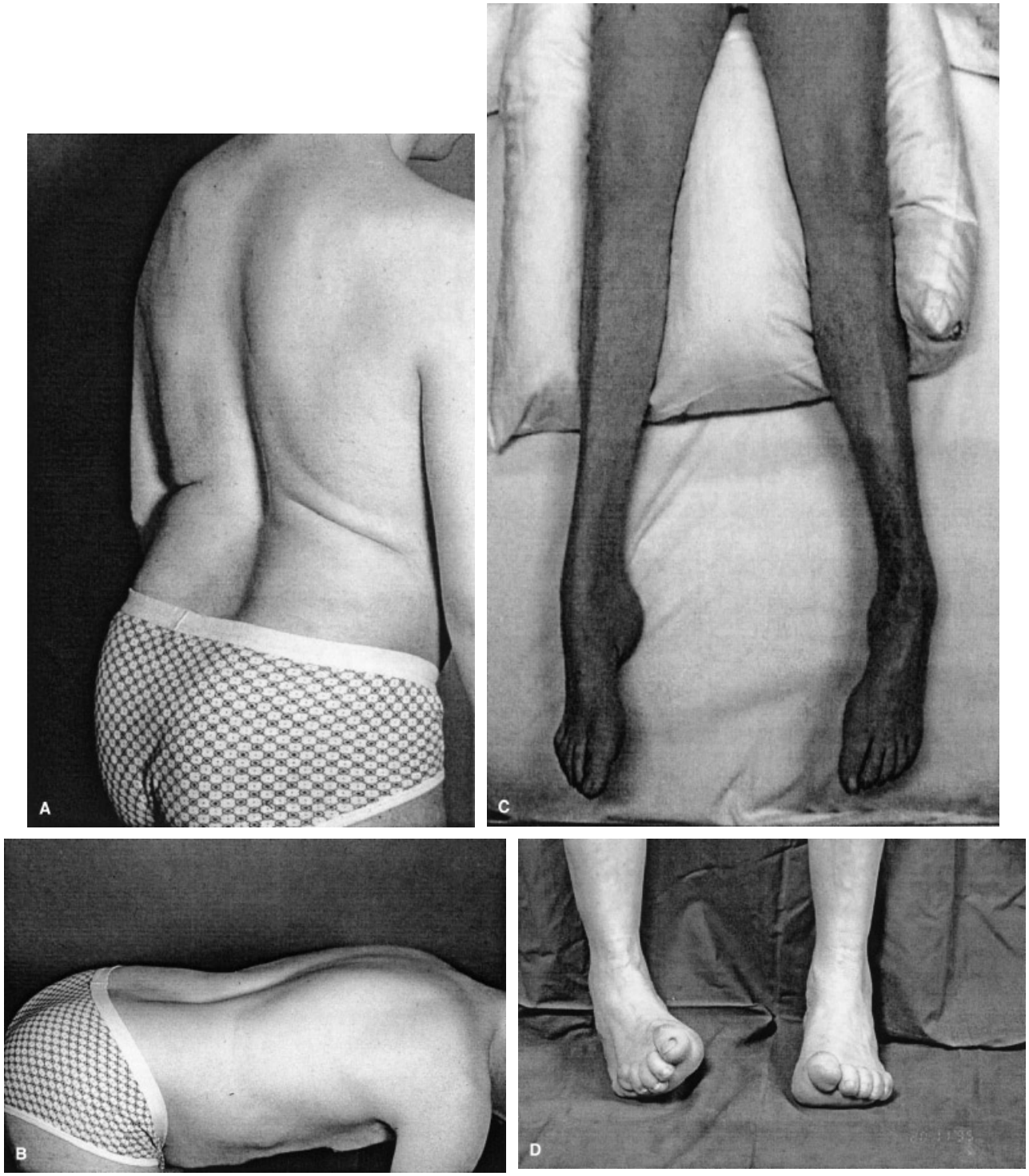

FIG. 1. A: Exaggerated lumbar lordosis in the stiff man syndrome with autoantibodies to glutamic acid decarboxylase (antiGADAb). The contour of the lumbar paraspinal muscles is accentuated and there is a transverse skin crease across the back reflecting contraction of the lateral oblique truncal muscles. **B:** Same patient bending forward, demonstrating the restriction in range of truncal movement caused by the axial muscle contraction. **C:** Leg spasms with extensor posturing. **D:** Foot posturing in the stiff man syndrome with antiGADAb.

clonic jerks of the legs and trunk and impaired truncal mobility may lead to unexplained falls without loss of consciousness that may be misdiagnosed as drop attacks or epilepsy or hysterical falls.

Autonomic Symptoms and Crises

Many patients exhibit autonomic signs comprising diaphoresis, pupil dilation, tachycardia, tachypnea, arterial hypertension, and hyperthermia. Repeated spasms in close succession, resembling tetanus, may be accompanied by acute life-threatening autonomic dysfunction necessitating intensive care management (Table 1). Sudden death occurs in approximately 10% of patients, due in most cases to acute autonomic failure.[11,12]

Other Clinical Features

Reflex abnormalities are frequent in the SMS with exaggerated tendon reflexes and loss of abdominal cutaneous reflexes (Table 1). Exaggerated startle responses to acoustic or tactile stimulation are seen in 60% of cases and may be associated with a brisk head retraction reflex. The incidence of epilepsy has been estimated to be 10 to 20%,[5,13] but this rate is much higher than found in our experience. The presence of otherwise unexplained epilepsy is suggestive of a diagnosis of PERM. More than 50% of patients report a distinct fear of open spaces (a corridor or room may be sufficient) that may induce spasms.[14] Paroxysmal fear, excessive startle, and emotionally induced spasms probably contribute to an initial misdiagnosis of hysteria in more than two thirds of patients.

Associated Conditions

The association of diabetes with the SMS was noted in Moersch and Woltman's original report. Indeed, one of their cases died of diabetic ketoacidosis. Insulin-dependent diabetes mellitus (11 of 36), autoimmune thyroid disease (4 of 36), pernicious anaemia (3 of 36), and vitiligo (2 of 36) were observed in the present cases. This finding is in accord with previous series of patients with antiGADAb and SMS demonstrating insulin-dependent diabetes mellitus in 30 to 60%, autoimmune thyroid disease in 10%, and pernicious anaemia in 5%.[2,5] Sicca syndrome and other autoimmune diseases also may be seen. The frequency of organ-specific endocrine antibodies is higher.

Course of the Illness

In the majority of patients, axial muscle stiffness and rigidity has an insidious onset. Some patients report transient prodromal symptoms such as episodic sudden stiffness of one or both legs, unexplained falls, or failure of gait ignition particularly during emotional stress.[14] Once established, there follows a slow progression over months or years. Eventually, the condition stabilises and may remain static for several years or even decades.

It is increasingly recognised that the condition can begin in one leg ("stiff leg syndrome"), then spread to axial muscles and the other leg. In these cases, it is necessary to distinguish between other causes of spinal rigidity such as structural spinal cord disease (see *Differential Diagnosis*).

PATHOPHYSIOLOGY

Continuous Motor Unit Activity

A crucial finding and an important diagnostic criterion is the presence of continuous motor unit activity that gives rise to the rigidity and persists despite attempted relaxation. Continuous motor unit activity is composed of motor unit potentials with normal morphology, there are no signs of denervation, and grouped rhythmic discharges or bizarre high frequency discharges do not occur. Continuous motor unit activity usually is most prominent in axial muscles, particularly thoracolumbar paraspinal and rectus abdominis muscles but can be found in leg and proximal arm muscles. Peripheral nerve conduction velocities are normal. The rigidity and continuous motor unit activity lessen or even disappear during sleep and after spinal or general anaesthesia, indicating a central source.

The origin of the continuous motor unit activity, rigidity, and spasms in SMS has been investigated using various electrophysiological techniques to dissect out the contributions from different levels of the motor system. Spinal motoneuron excitability and Renshaw cell function are normal.[13,15–19] The silent period after supramaximal peripheral nerve stimulation or a stretch reflex is also normal, in contrast to tetanus where motoneurones are hyperexcitable due to defective segmental inhibition.[20] These findings indicate that continuous motor unit activity (and spasms) are driven by inputs to spinal motoneurones. Reduced vibration-induced suppression of the soleus H-reflex[18,19,21–23] suggests a disorder of presynaptic inhibition of Ia terminals in the spinal cord.

Exteroceptive (Cutaneomuscular) Reflexes

Exteroceptive or cutaneomuscular reflexes are enhanced, habituate poorly, and spread as reflex spasms into muscles normally not involved in the reflex.[13,15,17,21,22,24,25] These findings point to enhanced spinal interneurone excitability, due to defects either within spinal interneuronal networks at a segmental level or their descending control. Nonpainful polysynaptic reflexes are characteristically exaggerated in both upper and lower limbs as well as the axial (paraspinal) muscles

(Fig. 2). These reflexes are readily elicited by peripheral nerve stimulation, are not evident in normal subjects or other causes of muscular hypertonia, and are an important diagnostic feature of the SMS.[17,22,26] These augmented reflexes differ from normal flexor withdrawal responses and consist of stereotyped sequences of muscle excitation and inhibition. The enhanced exteroceptive reflexes can be recorded in muscles remote from the site of stimulation. Figure 3 illustrates responses recorded in paraspinal and leg muscles following stimulation of a finger ditial nerve. The response morphology is similar to that shown in Figure 2 with an initial myoclonic burst at a short latency (50–70 msec) that is followed by a period of tonic activity. Auditory stimulation can also elicit a similar pattern of muscle activity (Fig. 4). In these examples there appears to be a patterned response travelling down the spinal cord, suggesting a widespread disorder in which descending control of spinal interneurones modulates and elaborates polysynaptic interneuronal networks and reflexes.

Exaggerated and abnormally patterned exteroceptive reflexes account for many of the stimulus-induced muscle spasms and jerks observed in the SMS. These responses begin with one or several myoclonic jerks at short intervals that are synchronous in antagonistic muscle pairs and are followed by prolonged tonic muscle activation (observed clinically as spasm). This pattern of enhanced reflex appears to be characteristic to the SMS.[17,22,26] The notion that enhanced polysynaptic spinal reflexes are released by a defect in descending control is supported by the finding of similar enhancement of the blink reflex and other exteroceptive brainstem reflexes.[17]

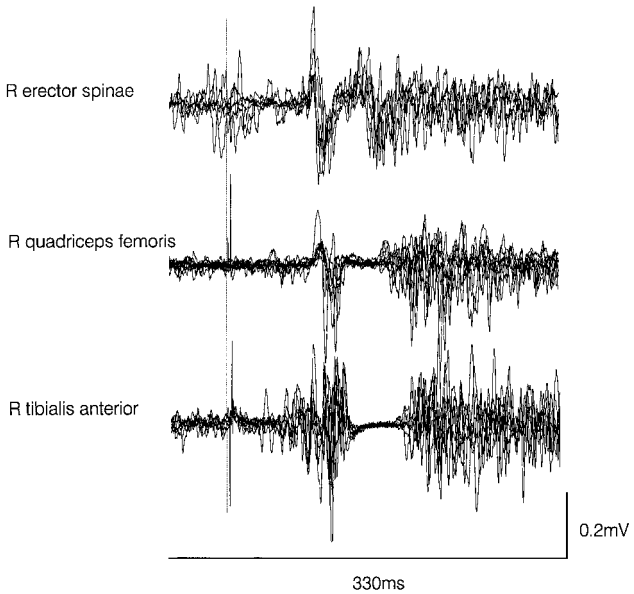

FIG. 2. Surface electromyographic recordings from the erector spinae and muscles of the right leg after paired stimulation of the right tibial nerve at the ankle in a patient with the stiff man syndrome. A series of individual trials are superimposed. Continuous muscle activity was present before the stimulus artefacts. Stimuli were delivered 50 msec after the onset of the sweep and are denoted by the paired stimulus artefacts. Note the initial brief myoclonic response (latency 66 msec in erector spinae) followed by the longer tonic increase in muscle activity in each muscle. The electromyographic activity corresponds to the observed myoclonic jerk and subsequent tonic posturing that follows cutaneous stimulation on clinical examination.

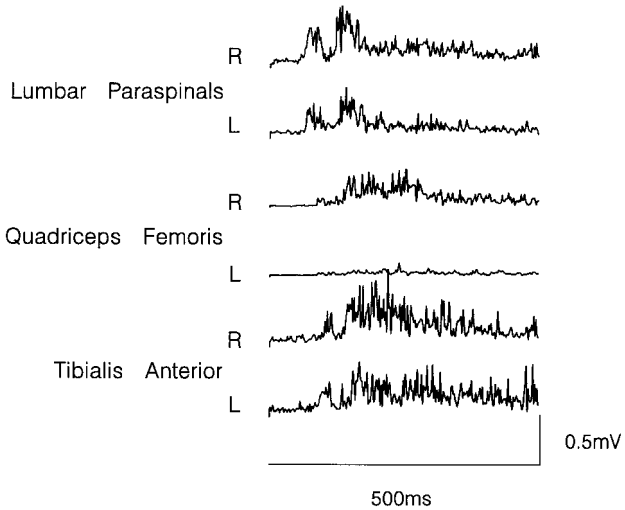

FIG. 3. Rectified surface electromyographic recordings from axial and leg muscles after stimulation of the digital nerve of the index finger (at the start of the sweep) in a man with the stiff-man syndrome. After stimulation, there is an initial myoclonic burst of activity followed by a prolonged tonic increase in muscle activity. The initial burst in the lumbar paraspinal muscles occurred approximately 60 msec after the stimulus.

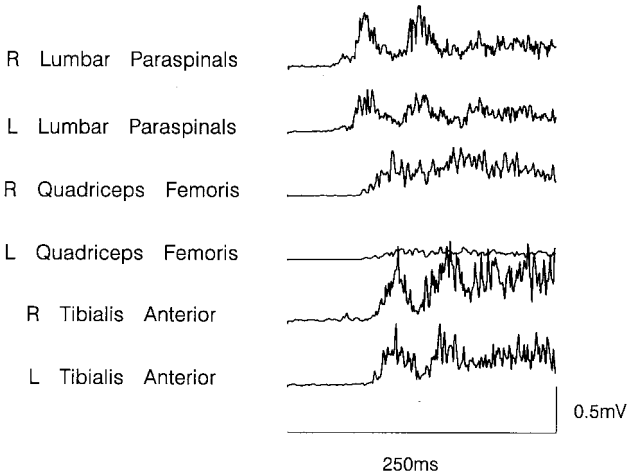

FIG. 4. Rectified surface electromyographic recordings from axial and leg muscles after auditory stimulation (delivered at the start of the sweep) in the same patient as in Figure 3. Brief myoclonic bursts of activity (beginning in lumbar paraspinal muscles approximately 50 msec after the tone) are followed by prolonged tonic discharge, as was seen after cutaneous stimulation.

Cortical Excitability

Intracortical inhibition within the motor cortex has been reported to be reduced in SMS, suggesting that reduced inhibitory GABAergic neurotransmission may lead to enhanced motor cortical excitability.[27,28]

Brainstem Myoclonus

Brainstem myoclonus, in which a generalised myoclonic response follows auditory or upper body stimulation (particularly taps to the jaw and head or supraorbital nerve stimulation) may be prominent in the SMS (Fig. 4). Prominent brainstem myoclonus in association with rigidity typical of SMS has been referred to as the "jerking stiff man syndrome"[29] and is discussed below. A prolonged tonic spasm also may follow the myoclonic jerk[16,29,30] leading to falls. This pattern has also been regarded as typical of PERM.[31] The relationship between brainstem myoclonus and the abnormally patterned blink and other brainstem reflexes is not clear.

Pharmacological Studies

Several studies have provided neuropharmacological evidence for an imbalance in noradrenergic and γ-aminobutyric acid (GABA) transmitter systems involved in central motor control, with relative overactivity in adrenergic descending reticulospinal systems, and reduced inhibitory GABA activity.[15–17,26,27,32,33] Monoaminergic reticulospinal pathways from the brainstem inhibit short latency spinal flexor reflex afferents and facilitate long latency spinal flexor reflex pathways.[34] Relative monoaminergic overactivity or reduced inhibitory GABAergic activity could contribute to the enhanced exteroceptive reflexes in SMS. Drugs that reduce monoaminergic effects, such as clonidine or tizanidine, and those enhancing GABA-ergic inhibition, such as baclofen and diazepam, diminish the severity of spasms and stiffness.

Although the muscle relaxant effect of diazepam is not specific, the response to intravenous diazepam is so prompt and dramatic that it is a useful diagnostic tool. Patients with SMS/PERM usually show dramatic normalisation of muscle tone at subhypnotic doses after the infusion of 5 mg of diazepam over 5 minutes (20 mg of diazepam diluted in 100 ml of saline). Over the next 5 minutes, the infusion is interrupted, and the patient is reexamined. This procedure can be repeated three times.[26]

ANCILLARY INVESTIGATIONS

Neuroimaging

Only a few patients have abnormalities on neuroimaging that may relate to their disease.[35,36] Magnetic resonance imaging helps mainly to exclude symptomatic cases.

AntiGADAb

Between 60 and 80% of patients with SMS, SLS, and PERM have serum antiGADAb.[2,37–40] Radioimmunoassays are the most sensitive and specific method of testing for antiGADAb,[38–41] increasing the detection of antiGAD65Ab to 98% of 46 cases of SMS in one report.[40] As serum antiGADAb may be present in other organ-specific autoimmune diseases, cerebrospinal fluid (CSF) examination is indispensable in confirming the intrathecal de novo antibody production.[41,42]

CSF

The CSF is abnormal in the majority of cases (Table 2). Oligoclonal immunoglobulin G (IgG) bands were found in 60% of the present cases, comparable with other studies.[42] The cell count, total protein, and IgG levels are less frequently elevated.[37,39] AntiGADAb are present in CSF as well as the serum.[2,39,41,42] In some patients, autoantibody levels are even higher in CSF than in serum,[39] which is uncommon in other neurological diseases.

DIFFERENTIAL DIAGNOSIS

Muscle stiffness, spasms, and cramps are common complaints.[43,44] Patients with fibromyalgia or related syndromes experience low back pain with tender, painful muscles, but rigidity, spasms, and abnormal posturing of the back are unusual. When there is considerable back pain with an abnormal truncal posture, and it is not clear whether this condition is antalgic or voluntary, the absence of both continuous motor unit activity when relaxed and of abnormal cutaneomuscular reflexes argues strongly against the diagnosis of SMS. The typical posture of an exaggerated lumbar lordosis is an important diagnostic clue to SMS. This finding has been emphasised as an essential finding[44] but lumbar paraspinal

TABLE 2. *Cerebrospinal fluid findings in 50 patients from the Heidelberg registry with the stiff man syndrome, stiff leg syndrome, and progressive encephalomyelitis with rigidity and myoclonus*

	SMS/SLS (n = 34)	PERM (n = 16)
Pleocytosis	3 (4–23/ul)	10 (4–34/ul)
Elevation total protein	7	7
Intrathecal IgG synthesis	4	4
Oligoclonal bands	19/32	10
CSF normal	14	2
CSF pathological	20	14

IgG, immunogbulin G; CSF, cerebrospinal fluid.

muscle contraction, when standing or lying, is not invariably accompanied by hyperlordosis.

Muscle rigidity associated with diseases of the basal ganglia, such as dystonia, is typically related to action or movement. Axial muscle rigidity and abnormal posturing in axial torsion dystonia is mainly present when standing or walking and generally subsides during rest when lying supine. Exteroceptive and startle reflexes have little influence on the increased muscle tone in basal ganglia diseases.

Myotonia and neuromyotonia typically appear more in distal than proximal muscle groups and are accompanied by characteristic clinical findings of stiffness, focal cramps, and delayed muscle relaxation after voluntary contraction. If continuous motor unit discharge is more prominent in distal than paraspinal or abdominal muscles, the diagnosis of SMS should be questioned. Electromyographic evidence of high-frequency discharges, multiplets, and fasciculations further distinguish peripheral motor axon hyperexcitability in neuromyotonia.

Myopathies with contractures affecting the spine include the rigid spine syndrome, myositis fibrosa,[45] Emery-Dreifuss dystrophy, and occasionally inflammatory myopathies. Contractures persist during sleep or narcosis. Where there is a strong suspicion of a paraspinal myopathy, magnetic resonance imaging of the paraspinal muscles may reveal muscle atrophy and fatty infiltration of muscle while electromyography and muscle biopsy should confirm the diagnosis.

Benign physiological cramps typically occur in a single muscle after prolonged exercise and when at rest. Physiological cramps are characterised by a painful muscle contraction, which can be "broken" or interrupted by stretching the affected muscle. Distal muscles are usually involved, but occasionally cramps are more generalised. Nevertheless, the focal or rarely multifocal nature of cramps distinguishes them from the more widespread involvement of limb and trunk muscles in a spasm in the SMS.

Segmental rigidity and spasms may also occur in a variety of diseases of the spinal cord, such as inflammatory myelitis, multiple sclerosis, paraneoplastic myelopathy, and brainstem and spinal cord tumours. Spinal arteriovenous malformations or spinal cord ischaemia may predominantly affect spinal interneurones, causing intense rigidity of the involved regions.[46–51]

The most important differential diagnosis of SMS is psychogenic movement disorder. Indeed, autonomic signs such as arterial hypertension or profuse sweating may be misinterpreted as indicating pronounced effort in patients with psychogenic symptoms. Patients with SMS often report the profound influence of emotion on their symptoms or the obvious benefit they derive from seemingly minor assistance such as a helping hand or even finger. This finding is very uncommon in a psychogenic motor disturbance. Distractability is prominent in most psychogenic movement disorders but is not seen in SMS. In all cases, determination of antiGADAb and neurophysiological tests are extremely helpful.

PATHOLOGY

Neuropathological examinations of the central nervous system in SMS are summarised in Table 3. Initial reports were normal or did not disclose any consistent findings.[1,6,8,11,52] Neuronal and spinal interneuronal loss was reported in others.[13,53–58] In several cases, perivascular lymphocytic cuffing in the brainstem and spinal cord with variable neuronal loss predominantly in the spinal cord was evident.[4,12,56,59,60]

In more recent studies, pathological findings have been reported in 6 cases positive for antiGADAb.[12,54–56,58] Perivascular inflammatory change was observed in 3 cases (Fig. 5).[12,56] Degeneration of anterior horn cells and neuronal loss in the spinal cord were found in 5 cases.[12,54–56,58] Eye movement abnormalities and other brainstem signs in keeping with a diagnosis of PERM were recorded in 2 of these cases. These observations highlight the emerging overlap between SMS and PERM and raise questions about the distinction between these syndromes when the onset of illness is not acute and the course is not rapidly progressive.

VARIANTS OF THE SMS

PERM

This condition presents with axial muscle stiffness, rigidity, and painful spasms similar to SMS (Table 1). The onset is subacute over weeks, and the duration of illness in reported cases has ranged from weeks to several years with exacerbations and remissions. In contrast to SMS, rigidity and spasms are often preceded or accompanied by sensory symptoms or brainstem signs of ataxia, vertigo, disturbances of ocular motility, and dysarthria (Table 3). Cranial nerve involvement has been prominent in pathologically confirmed cases with nystagmus, ophthalmoplegia, deafness, and dysphagia. Muscle wasting, weakness, and areflexia reflect segmental spinal pathology. Spasms and generalised myoclonus may be accompanied by profuse sweating and other autonomic signs. Plastic (uniform) rigidity throughout the range of passive limb movement is severe. Autonomic crises or even failure are frequent, and some cases show a rapid deterioration until death.[3,31,61–67] The cerebrospi-

TABLE 3. *Summary of the clinical features and pathological findings in patients presenting with stiffness, spasms, and rigidity with clinical diagnosis of the stiff man syndrome (SMS) or progressive encephalomyelitis with rigidity and myoclonus (PERM)*

Case	Clinical features	Diagnosis	Disease duration	Pathological findings
Moersch & Woltman (1956) (1)	Painful spasms and rigidity of axial muscles cranial nerves, sensation normal	SMS	10 years	Brain normal spinal cord not examined
Campbell & Garland (1956) (67)				
Case 1	Back stiffness, abdominal, leg myoclonus diabetes mellitus	Subacute myoclonic spinal neuroniti[a]	1 year	Widespread perivascular lymphocytic cuffing
Case 3	Abdominal, paraspinal, leg spasm, myoclonus	Subacute myoclonic spinal neuroniti[a]	months	Subacute encephalomyelitis
Asher (1958) (6)	Painful spasms and rigidity of trunk	SMS	11 years	Nonspecific changes in muscle CNS not reported
Sikes (1959) (53)	Painful spasms and rigidity of trunk	SMS		Segmental loss spinal interneurones
Trethowan et al. (1960) (52)	Rigidity trunk, legs, painful spasms cranial nerves, sensation normal	SMS	3 years	Senile changes in brain and cord
Kasperek & Zebrowski (1971) (3)	Painful spasms and rigidity, axial proximal limb and facial muscles oculomotor palsy, nystagmus	SMS encephalomyelitis[b]	2 years	Perivascular lymphocyte cuffing, brainstem cord gliosis, demyelination
Lhermitte et al. (1973) (61)	Stiffness, spasms of legs and trunk brisk reflexes, extensor plantars, ocular signs, proprioceptive loss	Brainstem encephalomyelitis[b]	38 months	Brainstem, cord perivascular lymphocyte cuffing gliosis, neuronal loss
Whiteley et al. (1976) (62) Case 1	Rigidity and spasms of limbs and trunk cranial nerves and sensation normal	PERM[a]	13 months	Brainstem, cord perivascular lymphocyte cuffing gliosis, neuronal loss, demyelination
Case 2	Rigidity and jerking of limbs trunk dysarthria, dysphagia	PERM	21 days	Brainstem, cord perivascular lymphocyte cuffing gliosis, neuronal loss
Howell et al. (1978) (63)	Rigidity of trunk and limbs, painful spasms, myoclonus, opsoclonus, divergent strabismus extensor plantars	PERM	26 months	Brainstem, cord perivascular lymphocyte cuffing gliosis, demyelination selective loss spinal interneurones
Martinelli et al. (1978) (13)	Rigidity of trunk and limbs, cranial nerves, sensation normal	SMS	9 years	Gliosis in bulbar olives, loss Purkinje cells neuronal loss substantia nigra loss motoneurones cervical cord
Goetz & Klawans (1983) (11)	Painful leg, back spasms, IDDM	SMS	9 years	Normal brain and muscle spinal cord not examined
Watanabe et al. (1984) (57)	Muscle rigidity, spasms	SMS	4.5 years	Atrophy gliosis ventral spinal cord, absence small, medium anterior horn cells of medial and intermediate zones perivascular lymphocytic cuffing
Nakamura et al. (1986) (59)	Neck, trunk, proximal leg rigidity spontaneous, stimulus induced spasms	SMS	3 years	Leptomeningeal perivascular lymphocyte cuffing neuronal loss medial anterior horn cells
Bateman et al. (1990) (75)	Stiffness, spasms arms, legs	Paraneoplastic encephalomyelitis	months	Perivascular lymphocytic infiltrate

nal fluid shows a mild lymphocytic pleocytosis with elevated protein and IgG levels (Table 2). Neurophysiological findings are similar to those of SMS with continuous motor unit activity. In addition, striking brainstem myoclonus has been a prominent feature in some cases.[31,64]

Pathological features include perivascular lymphocyte cuffing and infiltration and neuronal loss in the brain-

TABLE 3.—(*Continued*)

Case	Clinical features	Diagnosis	Disease duration	Pathological findings
Mitsumoto et al. (1991) (12)				
Case 1	Trunk, limb rigidity, painful spasms extensor spasms, opisthotonos, extensor plantars autonomic crises, IDDM, antiGADAb	SMS[b]	6 years	Focal perivascular gliosis lower brain stem, spinal cord chromatolysis lumbar anterior horn cells
Case 2	Trunk, leg rigidity, spasm, lumbar lordosis Parinaud's syndrome, dysphagia, autonomic crises oligoclonal bands CSF, antiGADAb, gastric parietal cell Ab	SMS[b]	8 years	Perivascular lymphocytic infiltration spinal cord, brainstem, basal ganglia
Meinck et al. (1994) (4)				
Case 4	Stiffness, spasms, jerks of trunk, legs shoulders, cranial nerves normal	SMS	5 years	Perivascular lymphocyte cuffing in brain and cord neuronal loss in cord
Armon et al. (1996) (60)	Spasms feet, legs, respiratory muscles extensor rigidity, falls, shaking oligoclonal bands CSF	SMS	3 years	Perivascular lymphocytic cuffing brain, spinal cord mononuclear infiltrate anterior horns chromatolysis lumbar motor neurones
Warich-Kirches et al. (1997) (55)	Neck stiffness, spasms, falls, vegetative crises lumbar lordosis IDDM, antiGADAb	SMS	12 months	Decreased GABAergic cells in cerebellar cortex atrophy Renshaw cells spinal cord
Barker and Marsden (1998) (109)	Not stated	PERM	weeks	Chronic leptomeningitis, polioencephalitis perivascular cuffing cerebral hemispheres, brainstem, spinal cord
Saiz et al. (1999) (54)	Spasms, rigidity leg, trunk NIDDM, antiGADAb autonomic crises	SMS	8 months	Vacuolar degeneration anterior horn cells
Ishizawa et al. (1999) (58)	Stiffness, rigidity legs, low trunk painful stimulus induced spasms antiGADAb, respiratory arrest	SMS	5 weeks	Loss spinal motor neurones in intermediate and medial ventral horn
Warren et al. (2001) (56)	Stiffness, spasms legs, axial rigidity, lumbar lordosis intestinal pseudo-obstruction, autonomic crisis supranuclear gaze palsy (preterminal) antiGADAb, thyrogastric autoantibodies	SMS	8 years	Generalised perivascular lymphocytic cuffing, loss medial anterior horn cells

Column 1 lists the author(s) with date of publication and reference number in parentheses. CSF, cerebrospinal fluid; IDDM, insulin-dependent diabetes mellitus; NIDDM, Non-insulin dependent diabetes mellitus.

[a]Denotes cases diagnosed as PERM on the basis of inflammatory pathology, but the absence of additional clinical features is consistent with SMS.

[b]Denotes cases diagnosed with SMS but additional clinical features, particularly brainstem and bulbar signs, suggested a diagnosis of PERM.

stem and cervical spinal cord (Table 3). In the pathological study of Howell and colleagues,[63] neuronal loss was most conspicuous in spinal central grey zones affecting spinal interneurones This distribution was postulated to account for rigidity by removing inhibitory interneuronal control of spinal alpha motoneurones. Mild anterior horn cell loss in the ventral horn was also present. Upper motor neurone signs and sensory loss in the legs were attributed to degeneration of the long tracts in the cervical spinal cord. The term "spinal neuronitis" or "interneuronitis" also has been used to describe this condition.[62,66–68]

Of the aforementioned 68 patients, 29 were identified on clinical grounds as having PERM (Table 1). In most, the disorder began with firm neurological signs, such as an ocular motor disturbance with stiffness and spasms

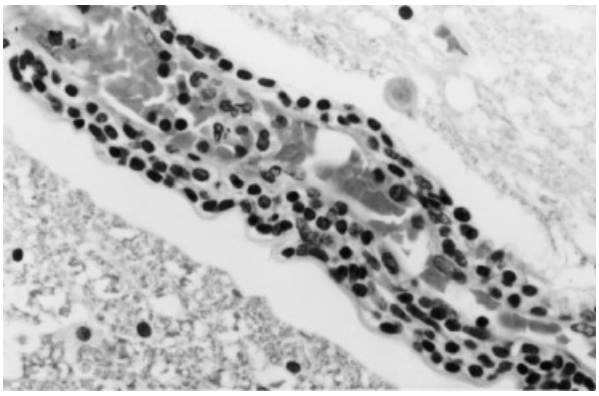

FIG. 5. Histological section from the lateral white matter of the spinal cord (T9) illustrating lymphocytic cuffing around a venule. Haematoxylin and eosin stain; original magnification, ×400. (Reproduced from Warren et al. (in press)[56] with the permission of the publisher).

developing later. The progressive course, cranial nerve, brainstem, and long tract signs distinguish PERM from SMS. However, the course of PERM is highly variable. In many cases, the additional neurological symptoms or signs suggestive of PERM are mild or transient. In others, there is a more protracted course, with typical clinical features of SMS but pathological changes of encephalomyelitis.[4,56,60] After many years, the SMS also may evolve into a clinical picture of PERM with the insidious development of new symptoms and signs such as retinopathy,[69] weakness, Babinski signs, or sensory loss.[12] The variability in the course of these cases necessitates regular diagnostic evaluation to define the clinical spectrum of these syndromes and establish any distinctions between them.[68] Indeed, the similarity in clinical findings (Table 1) and associated medical conditions, the prevalence of elevated antiGADAb, and the overlap in pathology (Table 3) suggests SMS and PERM are closely related.

Focal SMS: SLS

The SMS may begin in one limb, usually a leg.[70,71] These examples and 5 of the 6 cases presenting with SLS in the present series also had antiGADAb. The 2 cases described by Saiz and associates[70] also exhibited exaggerated exteroceptive reflex activity after repetitive stimulation of the tibial, median, and supraorbital nerves, typical of the SMS. Moreover, there is a considerable clinical overlap of SLS and SMS with the passage of time. One of our patients eventually diagnosed with PERM initially presented with unilateral leg stiffness and antiGADAb for 2 years, then evolved into typical SMS, and 6 years later developed dementia, progressive ataxia, and insulin-dependent diabetes mellitus. In cases of the SMS beginning in one limb, the leg is usually involved. Stiffness of one arm is suspicious for paraneoplastic SLS.[10,36] SLS has also been reported as a presumed localized spinal interneuronitis without progressing to involve the trunk and negative antiGADAb.[72]

Jerking Stiff Man Syndrome

The term "jerking stiff-man syndrome" was introduced by Leigh and coworkers[29] to describe a man who presented with axial and lower limb stiffness and rigidity that progressed over 9 years and was followed by the appearance of brainstem myoclonus and upper motor neurone signs. Alberca and colleagues[30] later described a similar patient in whom myoclonus followed a 14-year history of axial and lower limb stiffness and rigidity. In these cases, axial muscle rigidity affecting the abdominal and lumbar musculature with continuous motor unit activity was typical of SMS and persisted for many years before myoclonus developed, changing the clinical picture to one of PERM. The patient described by Brown and associates[31] (also reported by Burn et al.[73]) presented with extensive paraspinal and nuchal rigidity, brainstem myoclonus, diplopia, a supranuclear gaze palsy, consistent with PERM, and was found to have a range of autoimmune abnormalities, including antiGADAb.

Paraneoplastic Encephalomyelitis and SMS

Segmental or generalised muscle rigidity, spasms, and myoclonus, or weakness may be associated with malignancies. Breast and small cell lung cancer are the commonest.[10,36,74–79] Paraneoplastic SMS may be confined to the upper limbs, which is rare in typical SMS. Rapid progression within a few months to severe joint deformities[10] or even immobility is a feature suggestive of a paraneoplastic rigidity. Other clinical and neurophysiological features are indistinguishable from conventional SMS. However, paraneoplastic SMS may be accompanied by other manifestations such as a sensory ganglionopathy[80] mimicking PERM. Tests for anti-Yo, anti-Hu, or anti-Ri autoantibodies are usually negative. Autoimmunity in paraneoplastic SMS is directed against amphiphysin I, a synaptic vesicle protein, GAD, or both.[10,77–79] Neurological symptoms and signs may precede the discovery of cancer by several years.[36] Therefore, screening for a neoplasm is obligatory in patients with SMS, particularly at presentation and if there is rapid progression, with upper limb involvement and the development of fixed deformity of a limb. Most cases of paraneoplastic SMS patients respond poorly to diazepam, but many improve with steroids.

PATHOGENESIS

AntiGADAb and Other Autoantibodies

The role of autoimmunity against GAD in the pathogenesis of SMS is not yet clear. GAD is the rate-limiting enzyme in the synthesis of GABA, a major inhibitory transmitter. GABAergic neurons are so widely distributed within the central nervous system[81] that grey matter lesions would inevitably involve GABAergic neurons or synapses, which could lead to presentation of the immunogenic GAD molecule to B-cells and autoimmunity against GAD. However, the low prevalence of elevated antiGADAb levels among neurological patients, even those with neuroimmunological disorders,[82,83] suggests that autoimmunity against GAD is not simply an epiphenomenon of grey matter lesions but plays a more specific role in the pathogenesis of SMS and PERM. Another hypothesis is that autoimmunity in patients with SMS is primarily targeted against GABAergic neurons.[2,42] If this were the case, some correlation between individual autoantibody levels and symptoms or the course of the disease might be expected as in other autoimmune diseases. However, antiGADAb levels may vary considerably between patients[39] and fluctuate over years without any correlation with the clinical symptoms and signs and within one patient between tests (H.M.M., personal observation). On repeated testing, individual patients with low antibody levels may fluctuate between normal and abnormal values. Furthermore, there is no clear difference in the neurological presentation of patients with and without antiGADAb. In paraneoplastic SMS, serum autoantibodies against amphiphysin remain high, even when in complete remission.[10]

A variety of other organ-specific antibodies, particularly those associated with autoimmune endocrinopathies and the thyrogastric cluster, are found in SMS. Antibodies against pancreatic islet cells are found in 50 to 60% of cases, against gastric parietal cells in 50%, and against thyroid microsomes in 30 to 40%.[2,5,39,40] These antibodies are mainly found in association with antiGADAb. Pancreatic islet cell antibodies are also directed against GAD, but infrequently immunostain GABAergic neurones.[81] In our patients, 50% had one or more (up to four) autoimmune diseases, including type 1 diabetes mellitus, thyroiditis, pernicious anaemia, vitiligo, and the sicca syndrome, many of which began before the onset of the SMS. Moreover, antiGADAb and a susceptibility to organ-specific autoimmune diseases were found in the families of some patients.

The presence of antiGADAb is not confined to neurological syndromes. Elevated antiGADAb levels are found in type 1insulin-dependent diabetes mellitus and autoimmune endocrinopathies,[84–86] although the antibody levels are less than in the SMS.[84] Investigation of families with type 1 diabetic children showed that such susceptibility may have a genetic basis.[87]

Autoimmunity against GAD may be an epiphenomenon of susceptibility to autoimmune diseases rather than a primary pathological process directed against GABAergic neurons. However, some recent observations are not easily reconciled with this hypothesis. Almost all patients with SMS or PERM and antiGADAb also have an intrathecal de novo synthesis of these autoantibodies as shown by an elevated antibody specificity index.[41,42] The antibody specificity index (ASI) in many of them was higher than ASIs reported for infections of the central nervous system (CNS) such as neurosyphilis, human T-cell lymphotropic virus–associated myelopathy, or multifocal leucodystrophy.[88,89] The high ASI for antiGADAb suggests that these antibodies are being produced in the CNS. Accordingly, it appears from these data that SMS is an immune-mediated chronic encephalomyelitis. This notion would also be consistent with the pathological findings in some cases (Table 3).

Other Encephalopathies Associated with Autoimmunity Against GAD

Other neurological patients with antiGADAb, but without stiffness and spasms suffered focal epilepsy, palatal myoclonus, or ataxia.[82,90–96] Intrathecal de novo synthesis of antiGADAb in cases of focal epilepsy or ataxia[70,95] suggests these cases represent an immune-mediated chronic encephalitis. At this stage, it appears the spectrum of encephalomyelopathies associated with autoimmunity against GAD is wider than hitherto thought.

Other Autoantibodies in the SMS and Variants

Antibodies directed against amphiphysin I characterise the paraneoplastic variant of the SMS and may coexist with antiGADAb in breast cancer.[10] The significance of antibodies against gephyrin, a protein located at postsynaptic inhibitory membranes[97] or against an (as yet) unidentified 80-kDa neuronal target is not yet clear.[98]

TREATMENT

Symptomatic Treatment

Physiotherapy is helpful in some patients but may increase muscle tone and spasms in those with stimulus-induced jerks and spasms. Diazepam is widely used as the standard symptomatic drug treatment.[26,37,43,99] Oral baclofen or other antispastic or anticonvulsant drugs are less frequently effective. In many cases, habituation or

disease progression make increasing doses (up to 100 mg/day of diazepam) necessary. The risk of addiction and side effects such as sedation, depression, dysarthria, vertigo, or ataxia limit the applicability of chronic, high-dose, oral benzodiazepine therapy. A combination of benzodiazepines, muscle relaxants, or anticonvulsants may be helpful. Intrathecal baclofen may reduce frequency and intensity of spasms, normalise muscle tone, and increase overall mobility.[71,100–102] However, inadvertent cessation of intrathecal baclofen due to catheter rupture, pump failure, or erroneous refilling may lead to a potentially fatal withdrawal syndrome of acute autonomic failure and circulatory collapse.[100–102] Imminent autonomic failure is characterised by tachycardia, tachypnoea, arterial hypertension, and diaphoresis, and in SMS may be accompanied by frequent violent spasms requiring urgent intensive care and high doses of intravenous benzodiazepines. Therefore, intrathecal baclofen is a last-resort symptomatic treatment of SMS/PERM. Patients should permanently carry with them details informing others of the action necessary in such an emergency event.

Immunomodulation

Plasmapheresis, intravenous immunoglobulin (ivIgG), or corticosteroids have been successful in individual cases,[4,70,103–112] but this success has not been a universal experience.[113] A placebo-controlled, cross-over trial with ivIgG (2 g/kg body weight per month divided into two daily doses) over 3 months resulted in a decrease of stiffness and heightened sensitivity scores in the treatment group but not in the placebo group.[112] This effect declined over the following 2 months. Personal experience with a total of 67 immunomodulation therapies in 48 patients suggests that initial treatment with methylprednisolone (500 mg IV for 5 days) followed by maintenance oral methylprednisolone (tapering slowly from 100 mg daily to 10 mg or even less on alternate days) is superior to ivIgG (30 g per day for 5 days) or plasmapheresis (5 × 50 ml/kg body weight within 2 weeks).[114] Fifteen of 24 patients treated with this regimen reached minor impediment or even free mobility, compared with 2 of 15 for plasmapheresis, and 2 of 13 with ivIgG. The response to these immunomodulatory therapies was not dependent on antibody status, antibody level, or the diagnostic classification (PERM or SMS). It is important to note that the response to methylprednisolone treatment may develop over months. Therefore, in cases showing some response within 6 weeks, the low dose was continued over 1 or more years.

Acknowledgments: H.M.M. is indebted to the Volkswagenstiftung for generous support.

REFERENCES

1. Moersch FP, Woltman HW. Progressive fluctuating muscular rigidity and spasm (stiff-man syndrome): report of a case and some observations in 13 other cases. Mayo Clin Proc 1956;31:421–427.
2. Solimena M, Folli F, Aparisi R, Pozza G, De Camilli P. Autoantibodies to GABAergic neurons and pancreatic beta cells in stiff-man syndrome. N Engl J Med 1990;322:1555–1560.
3. Kasperek S, Zebrowski S. Stiff man syndrome and encephalomyelitis. Arch Neurol 1971;24:22–31.
4. Meinck HM, Ricker K, Hulser PJ, Schmid E, Peiffer J, Solimena M. Stiff man syndrome: clinical and laboratory findings in eight patients. J Neurol 1994;241:157–166.
5. Dalakas MC, Fujii, Li M, McElroy B. The clinical spectrum of antiGAD antibody positive patients with stiff person syndrome. Neurology 2000;55:1531–1535.
6. Asher R. A woman with the stiff-man syndrome. BMJ 1958;i:265–266.
7. O'Connor DCJ. Stiff man syndrome. Br Med J 1958;i:645.
8. Cohen L. Stiff man syndrome. Two patients treated with diazepam. JAMA 1966;195:160–162.
9. Gordon EE, Januszko DM, Kaufman L. A critical survey of stiff-man syndrome. Am J Med 1967;42:582–599.
10. Rosin L, De Camilli P, Butler M, et al. Stiff-man syndrome in a woman with breast cancer: an uncommon central nervous system paraneoplastic syndrome. Neurology 1998;50:94–98.
11. Goetz CG, Klawans HL. On the mechanism of sudden death in Moersch-Woltman syndrome. Neurology 1983;33:930–932.
12. Mitsumoto H, Schwartzman MJ, Estes ML, et al. Sudden death and paroxysmal autonomic dysfunction in stiff-man syndrome. J Neurol 1991;238:91–96.
13. Martinelli P, Pazzaglia P, Montagna P, Coccagna G, Rizzuto N, Simonati S, Lugaresi E. Stiff-man syndrome associated with nocturnal myoclonus and epilepsy. J Neurol Neurosurg Psychiatry 1978;41:458–462.
14. Henningsen P, Clement U, Kuchenhoff J, Simon F, Meinck HM. Psychological factors in the diagnoses and pathogenesis of stiff-man syndrome. Neurology 1996;47:38–42.
15. Mamoli B, Heiss WD, Maida E, Podreka I. Electrophysiological studies on the stiff-man syndrome. J Neurol 1977;217:111–121.
16. Boiardi A, Crenna P, Negri S, Merati B. Neurological and pharmacological evaluation of a case of Stiff-man syndrome. J Neurol 1980;23:127–33.
17. Meinck HM, Ricker K, Conrad B. The stiff man syndrome: new pathophysiological aspects from abnormal exteroceptive reflexes and the response to clomipramine, clonidine, and tizanidine. J Neurol Neurosurg Psychiatry 1984;47:280–287.
18. Rossi B, Massetani R, Guidi M, Mondelli M, Rossi A. Electrophysiological findings in a case of stiff man syndrome. Electromyogr Clin Neurophysiol 1988;28:137–140.
19. Floeter MK, Valls-Solé J, Toro C, Jacobowitz D, Hallett M. Physiological studies of spinal inhibitory circuits in patients with stiff-person syndrome. Neurology 1998;51:85–93.
20. Struppler A, Struppler E, Adams RD. Local tetanus in man. Arch Neurol 1963;8:62–78.
21. Isaacs H. Stiff man in a black girl. J Neurol Neurosurg Psychiatry 1979;42:988–994.
22. Meinck HM, Ricker K, Hulser PJ, Solimena M. Stiff man syndrome: neurophysiological findings in eight patients. J Neurol 1995;242:134–142.
23. Martinelli P, Nassetti S, Minardi C, Macri S, Ippoliti M. Electrophysiological evaluation of the stiff man syndrome: further data. J Neurol 1996;243:551–553.
24. Franck G, Cornette M, Grisar T, Moonen G, Gerebtzoff MA. Le syndrome de l'homme raide. Acta Neurol Belg 1974;74:221–240.
25. Stöhr M, Heckl R. Das Stiff man Syndrom. Klinische, elektromyographische und pharmakologische Befunde bei einem eigenen Fall. Arch Psychiatr Nervenkr 1977;223:171–180.

26. Meinck HM, Conrad B. Neuropharmacological investigations in the stiff-man syndrome. J Neurol 1986;233:340–347.
27. Sandbrink F, Syed NA, Fujii MD, Dalakas MC, Floeter MK. Motor cortex excitability in stiff person syndrome. Brain 2000; 123:2231–2239.
28. Koerner C, Weiland B, Meinck H-M. Motor cortical excitability in stiff man syndrome. Mov Disord 2000;15(Suppl. 3):76–77.
29. Leigh PN, Rothwell JC, Traub M, Marsden CD. A patient with reflex myoclonus and muscle rigidity: "the jerking stiff man syndrome." J Neurol Neurosurg Psychiatry 1980;43:1125–1131.
30. Alberca R, Remero M, Chaparro J. Jerking stiff-man syndrome. J Neurol Neurosurg Psychiatry 1982;45:1159–1160.
31. Brown P, Rothwell JC, Thompson PD, Britton TC, Day BL, Marsden CD. The hyperekplexias and their relationship to the normal startle reflex. Brain 1991;114:1903–1928.
32. Guilleminault C, Sigwald J, Castaigne P. Sleep studies and therapeutic trial with L-Dopa in a case of stiff-man syndrome. Eur Neurol 1973;10:89–96.
33. Schmidt RT, Stahl SM, Spehlmann R. A pharmacological study of the stiff-man syndrome. Neurology 1975;25:622–626.
34. Schomburg ED. Spinal sensorimotor systems and their surpaspinal control. Neurosci Res 1990;7:265–340.
35. Meinck HM, Ricker K. Long-standing stiff man syndrome: a particular form of disseminated inflammatory CNS disease? J Neurol Neurosurg Psychiatry 1987;50:1556–1557.
36. Schmierer K, Valdueza JM, Bender A, DeCamilli P, David C, Solimena M, Zschenderlein R. Atypical stiff-person syndrome with spinal MRI findings, amphiphysin autoantibodies, and immunosuppression. Neurology 1998;51:250–252.
37. Stayer C, Meinck HM. Stiff-man syndrome: an overview. Neurologia 1998;13:83–88.
38. Schmidli RS, Colman PG, Bonifacio E. Disease sensitivity and specificity of 52 assays for glutamic acid decarboxylase antibodies. Diabetes 1995;44:636–640.
39. Dinkel K, Meinck HM, Jury KM, Karges W, Richter W. Inhibition of gamma-aminobutyric acid synthesis by glutamic acid decarboxylase autoantibodies in stiff man syndrome. Ann Neurol 1998;44:194–201.
40. Walikonis JE, Lennon VA. Radioimmunoassay for glutamic acid decarboxylase (GAD65) autoantibodies as a diagnostic aid for stiff man syndrome and a correlate of susceptibility to type 1 diabetes mellitus. Mayo Clin Proc 1998;73:1161–1166.
41. Koerner C, Dinkel K, Richter W, Meinck H-M. Intrathecal synthesis of GAD autoantibodies in stiff man syndrome. Clin Neurophysiol 1999;110(Suppl. 1):S235.
42. Dalakas MC, Li M, Fujii M, Jacobowitz DM. Stiff person syndrome: quantification, specificity and intrathecal synthesis of GAD65 antibodies. Neurology 2001;57:780–784.
43. Thompson PD. Stiff muscles. J Neurol Neurosurg Psychiatry 1993;56:121–124.
44. Lorish TR, Thorsteinsson G, Howard FM. Stiff-man syndrome updated. Mayo Clin Proc 1989;64:629–636.
45. Ricker K, Seitz D, Trostdorf E. Myositis fibrosa generalisata and stiff man syndrome. Eur Neurol 1970;3:13–27.
46. Penry JK, Hoefnagel D, van den Noort S, Denny-Brown D. Muscle spasm and abnormal postures resulting from damage to interneurones in spinal cord. Arch Neurol 1960;3:500–512.
47. Suttenfield FD, Kost PF. The stiff man syndrome, report of a case. Am J Phys Med Rehabil 1964;43:214–216.
48. Tarlov IM. Rigidity in man due to spinal interneuron loss. Arch Neurol 1967;16:536–543.
49. Davis SM, Murray NMF, Diengdoh JV, Galea-Debono A, Kocen RS. Stimulus-sensitive spinal myoclonus. J Neurol Neurosurg Psychiatry 1981;44:884–888.
50. Rowland LP. Cramps, spasms and muscle stiffness. Rev Neurol 1985;141:261–273.
51. Martin R, Meinck HM, Schulte-Mattler W, Mertens HG. Borrelia burgdorferi myelitis presenting as a partial stiff man syndrome. J Neurol 1990;237:51–54.
52. Trethowan WH, Allsop JL, Turner B. The stiff-man syndrome. Arch Neurol 1960;3:14–22.
53. Sikes SZ. Stiff man syndrome (analysis and case report with spinal cord autopsy). Dis Nerv Syst 1959;20:254–258.
54. Saiz A, Minguez A, Graus F, Marin C, Tolosa E, Cruz-Sanchez F. Stiff man syndrome with vacuolar degeneration of anterior horn motor neurons. J Neurol 1999;246:858–860.
55. Warich-Kirches M, Von Bossanyi P, Treuheit T, et al. Stiff man syndrome: possible autoimmune aetiology targeted against GABA-ergic cells. Clin Neuropathol 1997;16:214–219.
56. Warren JD, Scott G, Blumbergs PC, Thompson PD. Pathological evidence of encephalomyelitis in the stiff man syndrome with anti GAD antibodies. J Clin Neurosci (in press).
57. Watanabe K, Shimizu T, Mannen T, Toyokura Y, Nagashima K. An autopsy case with unusual muscle rigidity resembling stiff man syndrome. Clin Neurol (Tokyo) 1984;24:839–847.
58. Ishizawa K, Komori T, Okayama K, et al. Large motor neuron involvement in stiff man syndrome: a quantitative and qualitative study. Acta Neuropathol (Berl) 1999;97:63–70.
59. Nakamura N, Fujiya S, Yahara O, Fujioka Y, Kawakami Y. Stiff-man syndrome with spinal cord lesion. Clin Neuropathol 1986; 5:40–46.
60. Armon C, Swanson JW, McLean JM, et al. Subacute encephalomyelitis presenting as stiff-person syndrome: clinical, polygraphic and pathological correlations. Mov Disord 1996;11:701–709.
61. Lhermitte F, Chain F, Escourolle R, Chedru F, Guilleminault C, Francoucal M. Un nouveau cas de contracture tetaniforme distinct du "stiff-man syndrome." Rev Neurol 1973;128:3–21.
62. Whiteley AM, Swash M, Urich H. Progressive encephalomyelitis with rigidity. Brain 1976;99:27–42.
63. Howell DA, Lees AJ, Toghill PJ. Spinal internuncial neurones in progressive encephalomyelitis with rigidity. J Neurol Neurosurg Psychiatry 1979;42:773–785.
64. Rothwell JC, Obeso JA, Marsden CD. Electrophysiology of somatosensory reflex myoclonus. Adv Neurol 1986;43:385–398.
65. McCombe PA, Chalk JB, Searle JW, Tannenberg AEG, Smith JJ, Pender MP. Progressive encephalomyelitis with rigidity: a case report with magnetic resonance imaging findings. J Neurol Neurosurg Psychiatry 1989;52:1429–1431.
66. Casado JL, Gil-Peralta A, Graus F, Arenas C, Lopez JM, Alberca R. Anti-Ri antibodies associated with opsoclonus and progressive encephalomyelitis with rigidity. Neurology 1994;44:1521–1522.
67. Campbell AMG, Garland H. Subacute myoclonic spinal neuronitis. J Neurol Neurosurg Psychiatry 1956;19:268–274.
68. Thompson PD. Stiff people. In: Marsden CD, Fahn S, editors. Movement disorders 3. Oxford: Butterworth Heinemann; 1994. p 372–405.
69. Steffen H, Menger N, Richter W, et al. Immune-mediated retinopathy in a patient with stiff-man syndrome. Graefe's Arch Clin Exp Ophthalmol 1999;237:212–219.
70. Saiz A, Graus F, Valldeoriola F, Valls-Solé J, Tolosa E. Stiff-leg syndrome: a focal form of stiff-man syndrome. Ann Neurol 1998; 43:400–430.
71. Thompson PD. Stiff man syndrome and related disorders. Parkinsonism Relat Disord 2001;8:147–153.
72. Brown P, Rothwell JC, Marsden CD. The stiff leg syndrome. J Neurol Neurosurg Psychiatry 1997;62:31–37.
73. Burn DJ, Ball J, Lees AJ, Behan PO, Morgan-Hughes JA. A case of progressive encephalomyelitis with rigidity and positive anti-glutamic acid dehydrogenase antibodies. J Neurol Neurosurg Psychiatry 1991;54:449–451.
74. Roobol TH, Kazzaz BA, Vecht CJ. Segmental rigidity and spinal myoclonus as a paraneoplastic syndrome. J Neurol Neurosurg Psychiatry 1987;50:628–631.
75. Bateman DE, Weller RO, Kennedy P. Stiffman syndrome: a rare paraneoplastic disorder? J Neurol Neurosurg Psychiatry 1990;53: 695–696.
76. Ferrari P, Federico M, Grimaldi LM, Silingardi V. Stiff-man

syndrome in a patient with Hodgkin's disease. An unusual paraneoplastic syndrome. Haematologica 1990;75:570–572.
77. De Camilli P, Thomas A, Cofiell R, et al. The synaptic vesicle-associated protein amphiphysin is the 128kD autoantigen of stiff-man syndrome with breast cancer. J Exp Med 1993;178:2219–2223.
78. Folli F, Solimena M, Cofiell R, Austoni M, Tallini G, Fassetta G, et al. Autoantibodies to a 128-kd synaptic protein in three women with the stiff-man syndrome and breast cancer. N Engl J Med 1993;328:546–551.
79. Dropcho EJ. Antiamphiphysin antibodies with small-cell lung carcinoma and paraneoplastic encephalomyelitis. Ann Neurol 1996;39:659–667.
80. Stingele R, Koelmel HW, Hilligardt B, von Maravic M, De Camilli P, Meinck HM. Two patients with stiff man syndrome, sensory neuronopathy and cancer. Mov Disord 1998;13(Suppl. 2): 208.
81. Mugnaini E, Oertel WH. An atlas on the distribution of GABAergic neurons and terminals in the rat CNS as revealed by GAD immunohistochemistry. In: Bjorklund A, Hokfelt T, editors. Handbook of chemical neuroanatomy, Vol. 4, Part 1. Amsterdam: Elsevier; 1985. p 436–608.
82. Saiz A, Arpa J, Sagasta A, et al. Autoantibodies to glutamic acid decarboxylase in three patients with cerebellar ataxia, late-onset insulin-dependent diabetes mellitus, and polyendocrine autoimmunity. Neurology 1997;49:1026–1030.
83. Meinck HM, Faber L, Morgenthaler N, et al. Antibodies against glutamic acid decarboxylase prevalence in neurological diseases. J Neurol Neurosurg Psychiatry 2001;71:100–103.
84. Baekkeskov S, Aanstoot H-J, Christgau S, et al. Identification of the 64K autoantigen in insulin dependent diabetes mellitus as the GABA-synthesising enzyme glutamic acid decarboxylase. Nature 1990;347:151–156.
85. Seissler J, Bieg S, Yassin N, Mauch L, Northemann W, Boehm BO, Scherbaum WA. Association between antibodies to the MR 67,000 isoform of glutamate decarboxylase (GAD) and type 1 (insulin-dependent) diabetes mellitus with coexisting autoimmune polyendocrine syndrome type II. Autoimmunity 1994;19: 231–238.
86. Tuomi T, Bjorses P, Falorni A, et al. Antibodies to glutamic acid decarboxylase and insulin dependent diabetes in patients with autoimmune polyendocrine syndrome type 1. J Clin Endocrinol Metabol 1996;81:1488–1494.
87. Schmidli RS, DeAizpurua HJ, Harrison LC, Colman PG. Antibodies to glutamic acid decarboxylase in at-risk and clinical insulin-dependent diabetic subjects: relationship to age, sex and islet cell antibody status, and temporal profile. J Autoimmun 1994;7:55–66.
88. Felgenhauer K, Reiber H. The diagnostic significance of antibody specificity indices in multiple sclerosis and herpes virus induced diseases of the nervous system. Clin Invest 1992;70:28–37.
89. Kitze B, Usuku K, Isumo S, Nakamura M, Shiraki H, Ijichi S, Yashiki S, et al. Density of antibody synthesis against HTLV-1 and its relation to HTLV-1 associated myelopathy. J Neurol 1996; 243:393–400.
90. Nemni R, Braghi S, Natali-Sora MG, Lampasona V, Bonifacio E, Comi G, Canal N. Autoantibodies to glutamic acid decarboxylase in palatal myoclonus and epilepsy. Ann Neurol 1994;36:665–667.
91. Honnorat J, Trouillas P, Thivolet C, Aguera M, Belin MF. Autoantibodies to glutamate decarboxylase in a patient with cerebellar cortical atrophy, peripheral neuropathy and slow eye movements. Arch Neurol 1995;52:462–468.
92. Abele M, Weller M, Mescheriakov S, Bork K, Dichgans J, Klockgether T. Cerebellar ataxia with glutamic acid decarboxylase autoantibodies. Neurology 1999;52:857–859.
93. Ikeda J, Harada T, Kamei H, Nakamura S. Autoantibody to glutamate decarboxylase in a patient with spinocerebellar degeneration and Sjorgen's syndrome. No To Shinkei 1998;50:177–180.
94. Giometto B, Nicolao P, Macucci M, Tavolato B, Foxon R, Bottazzo GF. Temporal lobe epilepsy associated with glutamic acid decarboxylase autoantibodies. Lancet 1998;352:457.
95. Peltola J, Kulmala P, Isojarvi J, Saiz A, Latvala K, Savola K, Knip M, et al. Autoantibodies to glutamic acid decarboxylase in patients with therapy resistant epilepsy. Neurology 2000;55: 46–50.
96. Trivedi R, Mundanthanam G, Amyes E, Lang B, Vincent A. Autoantibody screening in subacute cerebellar ataxia. Lancet 2000;2:565–566.
97. Butler HM, Hatashi A, Ohkoshi N, et al. Autoimmunity to gephyrin in stiff-man syndrome. Neuron 2000;26:307–312.
98. Darnell RB, Victor J, Rubin M, Clouston P, Plum F. A novel antineuronal antibody in stiff-man syndrome. Neurology 1993; 43:114–120.
99. Barker RA, Revesz T, Thom M, Marsden CD, Brown P. Review of 23 patients affected by the stiff man syndrome: clinical subdivision into stiff trunk (man) syndrome, stiff limb syndrome, and progressive encephalomyelitis with rigidity. J Neurol Neurosurg Psychiatry 1998;65:633–640.
100. Penn RD, Mangieri EA. Stiff-man syndrome treated with intrathecal baclofen. Neurology 1993;43:241–242.
101. Stayer C, Tronnier V, Dressnandt J, et al. Intrathecal baclofen therapy for stiff-man syndrome and progressive encephalomyelopathy with rigidity and myoclonus. Neurology 1997;49:1519–1597.
102. Meinck HM, Tronnier V, Marquardt G. Surgical treatment of stiff-man syndrome with intrathecal baclofen. In: Krauss JK, Jankovic J, Grossman RG, editors. Movement disorders surgery. Philadelphia: Lippincott, Williams and Wilkins; 2001. p 393–396.
103. Vicari AM, Folli F, Pozza G, et al. Plasmapheresis in the treatment of stiff-man syndrome. N Engl J Med 1989;320:1499–1499.
104. Brashear HR, Phillips LH. Autoantibodies to GABAergic neurons and response to plasmapheresis in stiff-man syndrome. Neurology 1991;41:1588–1592.
105. McEvoy KM, Ahslskog JE. Antibody positive stiff man syndrome responding to immunosuppression. Neurology 1991;41: 143–146.
106. Amato AA, Cornman EW, Kissel JT. Treatment of stiff-man syndrome with intravenous immunoglobulin. Neurology 1994;44: 1652–1654.
107. Karlson EW, Sudarsky L, Ruderman E, Pierson S, Scott M, Helfgott SM. Treatment of stiff-man syndrome with intravenous immune globulin. Arthritis Rheum 1994;37:915–918.
108. Fogan L. Progressive encephalomyelitis with rigidity responsive to plasmapheresis and immunosuppression. Ann Neurol 1996;40: 451–453.
109. Barker RA, Marsden CD. Successful treatment of stiff man syndrome with intravenous immunoglobulin. J Neurol Neurosurg Psychiatry 1997;62:426–427.
110. Hau W, Davis C, Hirsch IB, Eng LJ, Daniels T, Walsh D, Lernmark A. Plasmapheresis and immunosuppression in the stiff-man syndrome with type 1 diabetes: a 2-year study. J Neurol 1999;246:731–735.
111. Souza-Lima CF, Ferraz HB, Braz CA, Araujo AM, Manzano GM. Marked improvement in a stiff limb patient treated with intravenous immunoglobulin. Mov Disord 2000;15:358–359.
112. Dalakas MC, Fujii M, Li M, Lufti B, Kyhos J, McElroy B. High dose intravenous immunoglobulin for stiff person syndrome. N Engl J Med 2001;345:1870–1876.
113. Harding AE, Thompson PD, Kocen RS, Batchelor JR, Davey N, Marsden CD. Plasma exchange and immunosuppression in the stiff-man syndrome. Lancet 1989;2:915.
114. Meinck H-M. Immunomodulation in the stiff man syndrome. Mov Disord 2000;15(Suppl. 3):252–253.